



Patient **Susan Dick**
D.O.B. **17/12/1951**

NHS No **452 215 0296**
Patient Ref **3107012**

Reason Varicose vein
Outcome Incompetence

| | Right | | Left | |
|---------------------------|----------------|-------------------|----------------|-------------------|
| Deep Veins | Patency | Competency | Patency | Competency |
| Common Iliac Vein | | | | |
| External Iliac Vein | | | | |
| Internal Iliac Vein | | | | |
| Common Femoral Vein | | | Widely Patent | Competent |
| Profunda Vein | | | Widely Patent | Competent |
| Superficial Femoral Vein | | | Widely Patent | Competent |
| Popliteal Vein | | | Widely Patent | Competent |
| Posterior Tibial Vein | | | Patent | Competent |
| Anterior Tibial Vein | | | Patent | Competent |
| Peroneal Vein | | | Patent | Competent |
| Soleal Vein | | | Patent | Competent |
| Gastrocnemius | | | Patent | Competent |
| Superficial Veins | | | | |
| Saphenofemoral Junction | | | Patent | Competent |
| L Saphenous Vein Above | | | see notes | |
| L Saphenous Vein Below | | | Not Identified | |
| Vein of Giacomini | | | Patent | Competent |
| Saphenopopiteal Junction | | | Not Identified | |
| S Saphenous Vein | | | Patent | Competent |
| Evidence of D.V.T. | | | | |
| Above the knee | | | No | |
| Popliteal | | | No | |
| Below the knee | | | No | |

Notes**LEFT LOWER LIMB VENOUS DUPLEX ASSESSMENT:**

Challenging scan due to patient discomfort during augmentation.

Iliac veins not viewed. Flow in the common femoral vein is phasic with respiration and responds normally to a Valsalva manoeuvre, suggesting proximal vein patency. All visualised deep veins appear widely patent/patent and competent with no evidence of previous DVT.

All measurements are proximal to the medial malleolus unless otherwise stated.

Sapheno-femoral junction (SFJ) is competent. A short segment of incompetent Long Saphenous vein (LSV), measures 6cm from the groin, identified in the proximal thigh, which appears to give rise to the thigh

Assessed by Sharifa Kiyegga

Printed on 01/02/2019 at 11:56 am

Checked by _____



Varicose Vein

C Chan

Examined 01/02/2019 08:50

Page 2 of 2

Reference

Accession CR-19-0000523

Patient Susan Dick

NHS No 452 215 0296

D.O.B. 17/12/1951

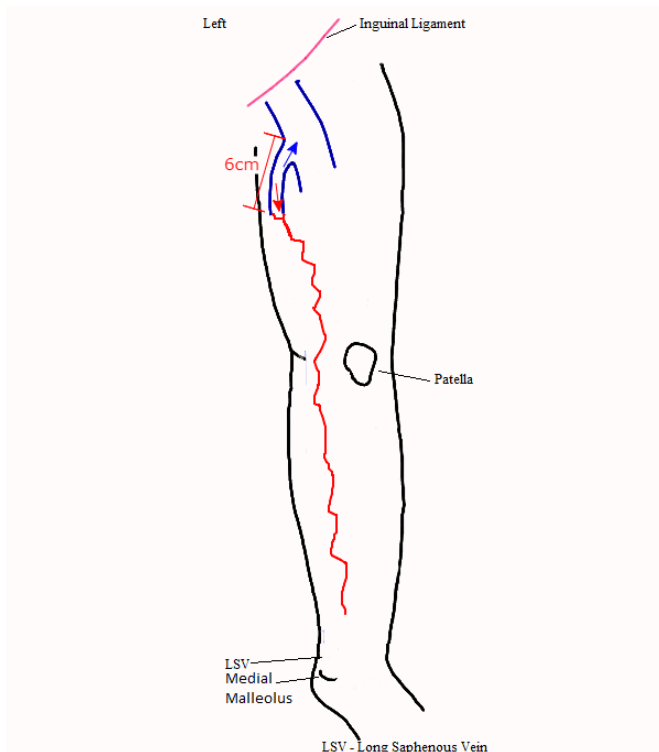
Patient Ref 3107012

varicose veins. LSV not identified in the mid to distal thigh and calf. Two perforators identified in the medial calf, however both appear competent.

Transverse (AP) dimensions of LSV: Proximal thigh - 0.42cm.

Sapheno-popliteal junction (SPJ) was not identified.

Short Saphenous vein (SSV) is competent and is continuous with a competent vein of Giacomini.



Assessed by Sharifa Kiyegga

Printed on 01/02/2019 at 11:56 am

Checked by